



Original Research Article

COMPARISON OF COMPUTED TOMOGRAPHY FINDINGS WITH HISTOPATHOLOGICAL FINDINGS IN PATIENTS WITH PANCREATIC CANCER: A RETROSPECTIVE STUDY

Suwendu Kumar Mohapatra¹, Jyotsana Goyal², Bagmi Mishra³, Jyotiranjana Mohapatra⁴, Subrat Kumar Samantara⁵, Subhansu Kumar Hota⁶

¹Associate Professor, Department of Radiodiagnosis, A.H. Post-graduate Institute of Cancer, Cuttack, India.

²Minimal Access and Robotic Surgical Oncology Fellow, Aster CMI hospitals Bangalore, India

³Assistant Professor, Department of Pathology, Sum Hospital II, Bhubaneswar, Odisha, India.

⁴Assistant Professor, Department of General Surgery, Shri Jagannath Medical College and Hospital, Puri, Odisha, India.

⁵Associate Professor, Department of Surgical Oncology, A.H. Post-graduate Institute of Cancer, Cuttack.

⁶Associate Professor, Department of Pathology, S.C.B. Medical College and Hospital, Cuttack, India.

Received : 04/11/2024
Received in revised form : 22/12/2024
Accepted : 06/01/2025

Corresponding Author:

Dr. Jyotiranjana Mohapatra,
Assistant Professor, Department of
General Surgery, Shri Jagannath
Medical College and Hospital, Puri,
Odisha, India.
Email: ?

DOI: 10.70034/ijmedph.2025.1.31

Source of Support: Nil,
Conflict of Interest: None declared

Int J Med Pub Health
2025; 15 (1); 177-182

ABSTRACT

Background: Pancreatic cancer (PC) represents a significant cause of mortality in developing countries. While Multi-Detector Computed Tomography (MDCT) provides valuable imaging data for staging pancreatic cancer, accurate diagnosis can be challenging due to factors such as fibrosis and inflammation, which can mimic tumor characteristics. Histopathological examination, although considered the gold standard for definitive diagnosis, is invasive and may not always be readily available. This study aimed to characterize the characteristic MDCT imaging features of pancreatic cancer and correlate these findings with histopathological findings to improve diagnostic accuracy.

Material and Methods: This retrospective cross-sectional study was carried out involving 23 PC patients treated at A.H Post-graduate Institute of Cancer, Cuttack over two years (January 2023 to December 2024). Only patients with complete medical records and a confirmed histopathological diagnosis were included. Data analysis was performed using IBM SPSS version 26.0. Descriptive statistics were presented through frequency tables and proportions, while chi-square tests were used to evaluate the relationship between CT scan results and histopathological findings.

Results: Our study indicated that 60% of patients were male and 56% of patients were between age group 21-40 years. In CT scan, 52% of patients had tumor in the head of the pancreas. Secondary signs were present in 17 (73.9%). Hypodense areas were seen in 17 (73.9%) before and 19 (82.6%) after contrast. Histopathology showed 9 (39%) with poorly differentiated adenocarcinoma. Fibrosis and necrosis were also found in 10 (43%) and 6 (26%) patients, respectively. Our study found significant associations between CT and pathological stages ($p = 0.00$), fibrosis presence and cancer location ($p = 0.00$), and necrosis with post-contrast density ($p = 0.03$).

Conclusion: This study demonstrates the high diagnostic accuracy of MDCT in characterizing pancreatic cancer, with findings closely correlating with histopathological results. The majority of tumors was located in the pancreatic head and exhibited hypodense areas on imaging. The strong concordance between MDCT findings and histopathology underscores its crucial role as a non-invasive tool for staging and guiding treatment decisions in pancreatic cancer, particularly in resource-constrained settings.

Keywords: CT Pattern, Histopathology, Pancreas Cancer, Ethiopia.

INTRODUCTION

The pancreas is a J-shaped organ situated retroperitoneally and is closely associated with peritoneal ligaments. While primarily retroperitoneal, a small portion of the pancreatic tail extends into the lienorenal ligament, occupying an intraperitoneal position. Anatomically, it is divided into five distinct sections: the head, uncinate process, neck, body, and tail.^[1] Physiologically, the pancreas plays a crucial role in both endocrine and exocrine functions.^[2] It serves as the primary site for insulin and glucagon production, regulating blood glucose levels. Moreover, it secretes somatostatin to modulate hormone release and produces digestive enzymes and bicarbonate, essential for nutrient breakdown and neutralization of gastric acid in the small intestine.^[3]

Pancreatic cancer (PC), originating in the organ behind the stomach, presents a significant clinical challenge with a high mortality rate globally.^[4] Recent reports indicate a global incidence of 49.8 cases and mortality of 57.7 deaths per million, with a 55%, 63%, and 53% increase in incidence, prevalence, and mortality rates, respectively, over the past 25 years.^[5] Developed nations exhibit the highest incidence and mortality rates, attributed to factors such as an aging population, unhealthy lifestyles, and the prevalence of metabolic disorders.^[6] The prevalence of PC in India is comparatively low relative to global figures but it is still a leading cause of cancer-related deaths. It is hypothesized that due to the changing lifestyle globally and, in India, the rates of PC will increase in the near future.^[7]

PC exhibits a dismal five-year survival rate of 4%, largely attributed to its aggressive biological behavior and often insidious presentation.^[8] The lack of specific early symptoms frequently results in delayed diagnosis, allowing the disease to progress to advanced stages with a poor prognosis.^[9] Furthermore, the diverse histological subtypes and overlapping symptomatology with other gastrointestinal conditions further complicate its early detection.^[10] Consequently, timely diagnosis of PC is paramount for improving patient outcomes.

Accurate staging and treatment planning of pancreatic ductal adenocarcinoma (PDA) necessitate precise imaging-based diagnosis.^[11] While both computed tomography (CT) and magnetic resonance imaging (MRI) are utilized, multidetector-row computed tomography (MDCT) plays a pivotal role due to its ability to generate high-resolution images, enabling detailed visualization of pancreatic anatomy.^[12,13] This facilitates accurate assessment of tumor size, location, extent of disease, and involvement of surrounding structures. Furthermore, MDCT aids in differentiating benign from malignant lesions and guides interventional procedures, such as biopsies, by precisely targeting the region of interest.^[14,15]

Integrating MDCT findings with histopathological analysis significantly enhances the diagnostic accuracy of PC. This combined approach improves the characterization of pancreatic lesions, aiding in the differentiation of benign from malignant conditions and clarifying ambiguous cases. This study aims to contribute to the body of knowledge by investigating the characteristic MDCT imaging patterns of PC and correlating them with histopathological findings in an Indian population. Given the limited radiologic research in developing countries like India, particularly in the Odisha region, this study will provide valuable insights for clinicians in this setting.

MATERIALS AND METHODS

Study design and setting

This study employed a retrospective cross-sectional design, analyzing data from patients diagnosed with pancreatic cancer at A.H. Post-graduate Institute of Cancer (AHPGIC), Cuttack, India. The study period spanned January 2023 to December 2024. AHPGIC, serving as the sole regional cancer center in Odisha, caters to a large patient population, with an estimated annual volume of approximately 100,000 individuals. The source population encompassed all patients who underwent CT scans and pathological evaluations for the management of pancreatic cancer.

Inclusion Criteria: Participants with complete medical records and a definitive histopathological diagnosis was included.

Exclusion Criteria: Patients with incomplete medical records or missing charts were excluded.

The clinical data such as age, sex, histologic type, fibrosis, and necrosis whereas the dependent variables were the size, pre-contrast density, post-contrast enhancement, and secondary sign of CT findings were collected from the patient record.

The data were imported into the Statistical Package for Social Science (SPSS) version 26.0 (IBM, USA) for analysis. Frequency tables and descriptive statistics were used to present the patients sociodemographic characteristics and patterns of CT scans and histopathological findings. The association between CT scan results and histopathological findings was assessed using chi-square tests. Finally, the results were reported through narratives, graphs, and charts.

As the study was a retrospective cross-sectional design, obtaining written or verbal informed consent from individual participants was not deemed necessary. All data extracted from patient charts were treated with strict confidentiality and used exclusively for the study's objectives.

RESULTS

Socio-demographic Characteristics

This is a retrospective study based on the medical records of 23 pancreatic cancer patients who

underwent CT scans and histopathological examinations between January 2023 and December 2024 at AHPGIC, Cuttack. Most participants were between 40 and 60 years old, with a median age of 51. [Table 1]

CT pattern of pancreatic cancer patients

The majority of patients (52%) had pancreatic cancer located in the head of the pancreas, followed by the body 7 (30%). Additionally, 17 (73%) of participants exhibited secondary signs, with 16 (69%) showing biliary tree dilation and 11 (47%) experiencing pancreatic upstream parenchyma atrophy. Regarding tumor characteristics, 60.9% of patients had a CT tumor size between 2-5 cm, and 69% had a CT stage of T2. [Table 2]

Among the PC patients, 17 (73.9%) and 19 (82%) exhibited hypo-dense areas before and after contrast enhancement respectively. Additionally, 1 patient (4%) had heterogeneous density before contrast, and 11 % demonstrated peripheral enhancement with central hypodense areas after contrast. [Figure 1]

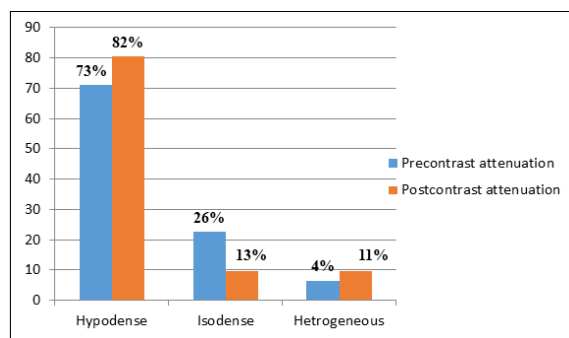


Figure 1: Pattern of pre and post-contrast attenuation/density of pancreatic cancer patients.

Histopathological findings of the pancreatic cancer patients.

Histologically, five (21%) patients were diagnosed with the well-differentiated type of adenocarcinoma, while two (8 %) patients had the papillary form of

pancreatic cancer. However, the majority, nine (39%) participants, had poorly differentiated adenocarcinoma. [Figure 2]

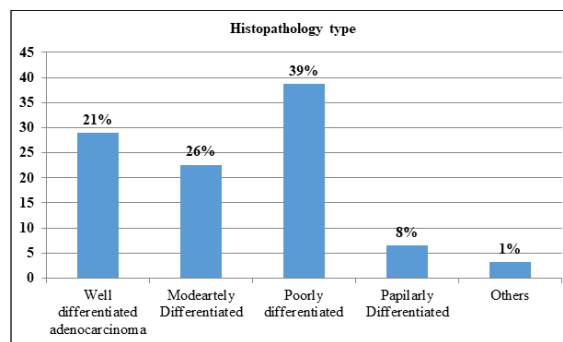


Figure 2: Histological findings of pancreatic cancer patients.

Pathological findings of the pancreatic cancer patients.

Pathologically, most participants, 13 (56%), were at the P3 stage. The study also found that 10 patients (43%) with pancreatic cancer exhibited fibrosis, while six patients (26%) showed evidence of necrosis. [Table 3]

Association between Computed tomography pattern of pancreas cancer and histopathological findings The relationship between CT findings and pathological features of pancreatic cancer was assessed using the chi-square and Fisher's exact tests. The study demonstrated a strong, statistically significant association between the CT stage and pathological stage (p-value = 0.002). Additionally, the presence of fibrosis in Histological analysis was significantly linked to the location of pancreatic cancer (p-value = 0.0001). Necrosis also showed a significant association with post-contrast density/attenuation (p-value = 0.01).

Table 1: Socio-demographic characteristics of pancreatic cancer patients

Variables	Frequency(N=23)	Percentage (%)
Age group	<20	0
	21-40	13
	41-60	6
	>61	4
Sex	Male	14
	Female	9

Table 2: CT pattern of pancreas cancer patients

CT Pattern	Frequency (N= 23)	Percentage (%)
Location	Head	12
	Neck	3
	Body	7
	Tail	1
Secondary sign	Yes	17
	No	6
Pancreatic duct dilatation	Yes	16
	No	7
Upstream pancreatic body atrophy	Yes	11
	No	12
Tumor size	<2cm	5
	2-5cm	14

	>5cm	4	17.4
CT stage	T1	1	4.3
	T2	16	69.6
	T3	6	26.1

Table 3: Pathological findings of pancreas cancer patients

Pathological findings		Frequency (N= 31)	Percentage (%)
Pathologic Stages	pT1	1	4.3
	pT2	7	30.4
	pT3	13	56.5
	pT4	2	8.7
Fibrosis	Yes	10	43.5
	No	13	56.5
Necrosis	Yes	6	26.1
	No	17	73.9

DISCUSSION

This study investigated the characteristic MDCT appearance of pancreatic cancer and its correlation with histopathological findings. The majority of patients in this study presented with pancreatic head tumors, consistent with findings from other studies reporting a high prevalence of head-of-pancreas tumors in the Netherlands (71%), Ohio (67.5%), and the USA (56%).^[16] This predilection for head-of-pancreas involvement may be attributed to several factors, including a higher concentration of ductal cells, proximity to vital structures like the bile duct and duodenum, and a rich blood and lymphatic supply.^[17] In contrast, tumors arising in the pancreatic body or tail may remain asymptomatic for longer due to their deeper location, often leading to delayed diagnosis and advanced disease at presentation.^[18]

This study observed secondary upstream pancreatic parenchymal atrophy in 47.8% of participants. Tumor size distribution demonstrated that 60.9% of cases ranged from 2 to 5 cm, with 69.6% classified as CT stage T2. These findings align with observations from studies conducted in China, Japan, and Tokyo.^[19-20] Upstream pancreatic atrophy is a recognized phenomenon in pancreatic cancer, primarily attributed to obstruction of the pancreatic duct by the tumor. This obstruction impedes the flow of pancreatic enzymes, leading to nutrient deprivation and subsequent atrophy of the pancreatic parenchyma. Furthermore, the increased intraluminal pressure resulting from the obstruction can exacerbate tissue damage, contributing to parenchymal degeneration.^[21-22]

The majority of participants (73% and 82% before and after contrast administration, respectively) exhibited hypodense attenuation on CT scans. This finding is consistent with the known characteristics of pancreatic tumors. Dense fibrotic stroma within the tumor, inadequate blood supply leading to poor contrast enhancement, and areas of necrosis within the tumor can all contribute to the observed hypodense appearance on imaging.^[23,24] These findings are further supported by our observation of fibrosis in 43% of participants.

Histopathological examination revealed that 39% of the tumors exhibited a poorly differentiated

phenotype. This finding is consistent with observations from a Brazilian study,^[25] although a higher proportion of well-differentiated tumors (35.4%) were reported in a Japanese cohort.^[26] These variations may reflect differences in patient demographics, environmental factors, and genetic predispositions across different populations.

This study investigated the association between CT scan findings and histopathological characteristics of pancreatic cancer. A significant correlation was observed between the presence of fibrosis on histology and the location of the tumor within the pancreas. This finding aligns with the known propensity for pancreatic head tumors to exhibit a greater degree of fibrosis, likely attributed to the region's unique anatomical and physiological characteristics, including proximity to critical structures and a higher prevalence of chronic inflammation.^[27] The desmoplastic reaction, characterized by dense collagen deposition and fibrotic tissue formation, is prominent in this region, influencing tumor behavior and potentially contributing to fibrosis.^[28] These findings underscore the importance of considering tumor location in understanding tumor biology and guiding treatment strategies, particularly in managing fibrosis-related complications.

This study demonstrates a strong, statistically significant correlation between CT-based tumor staging and the pathological stage. These findings highlight the effectiveness of CT in assessing the extent and severity of pancreatic cancer, aligning closely with the gold standard of histopathological evaluation.^[29] This is particularly significant in resource-limited settings like India, where CT offers a valuable, non-invasive, and cost-effective option for initial staging and treatment planning. By accurately predicting disease progression, CT enables timely interventions and optimizes the utilization of limited healthcare resources.

This study demonstrates a significant association between post-contrast attenuation patterns on CT scans and the presence of necrosis within pancreatic tumors. This finding is consistent with the pathophysiology of necrosis, characterized by decreased cellular density due to cell death and breakdown of cellular structures, resulting in reduced

contrast enhancement. Factors such as poor blood supply to necrotic areas, fluid accumulation within necrotic regions, and the presence of a desmoplastic stroma likely contribute to the observed hypodense appearance on CT images.^[30]

CONCLUSION

This study emphasizes the crucial role of multidetector computed tomography (MDCT) in characterizing pancreatic cancer by demonstrating a strong correlation between imaging findings and histopathological features. Most tumors were located in the pancreatic head, with hypodense areas on MDCT frequently associated with dense fibrosis, poor blood supply, and necrosis. These findings underscore the importance of MDCT as a non-invasive tool for accurate staging and treatment planning. By facilitating timely and informed clinical decision-making, MDCT contributes to improved patient outcomes and optimized healthcare resource utilization, particularly in resource-limited settings.

Declarations

Ethical Approval and Consent to participate

Not applicable as retrospective nature of study

Consent for publication

Not applicable as retrospective nature of study.

Availability of supporting data

Upon request to the corresponding author

Competing interests

Nil

Funding Statement

Nil

Authors 'contributions: All authors made substantial contributions to the reported work, including in the areas of conception, study design, execution, data collection, analysis, and interpretation. They participated in drafting, revising, and critically reviewing the article, gave final approval for the version to be published, agreed on the journal for submission, and accepted responsibility for all aspects of the work.

REFERENCES

1. Chauhan A, Elsayes KM, Sagebiel T, Bhosale PR. The pancreas. Cross-Sectional Imaging of the Abdomen and Pelvis: A Practical Algorithmic Approach. 2015:189-227.
2. Pandol SJ. Normal pancreatic function. Pancreapedia: The Exocrine Pancreas Knowledge Base. 2015.
3. Röder PV, Wu B, Liu Y, Han W. Pancreatic regulation of glucose homeostasis. *Experimental & molecular medicine*. 2016; 48(3):e219-e.
4. Ilic M, Ilic I. Epidemiology of pancreatic cancer. *World journal of gastroenterology*. 2016; 22(44):9694.
5. Lippi G, Mattiuzzi C. The global burden of pancreatic cancer. *Archives of Medical Science*. 2020; 16(1).
6. Huang J, Lok V, Ngai CH, Zhang L, Yuan J, Lao XQ, et al. Worldwide Burden of, Risk Factors for, and Trends in Pancreatic Cancer. *Gastroenterology*. 2021; 160(3):744-54.
7. Gaidhani RH, Balasubramaniam G. An epidemiological review of pancreatic cancer with special reference to India. *Indian J Med Sci* 2021; 73(1):99-109.
8. Luo J, Xiao L, Wu C, Zheng Y, Zhao N. The incidence and survival rate of population-based pancreatic cancer patients: Shanghai Cancer Registry 2004–2009. *PLoS one*. 2013;8(10):e76052.
9. Tummers W, Groen J, Sibinga Mulder B, Farina-Sarasqueta A, Morreau J, Putter H, et al. Impact of resection margin status on recurrence and survival in pancreatic cancer surgery. *Journal of British Surgery*. 2019;106(8):1055-65.
10. Pereira SP, Oldfield L, Ney A, Hart PA, Keane MG, Pandol SJ, et al. Early detection of pancreatic cancer. *The Lancet Gastroenterology & Hepatology*. 2020;5(7):698-710.
11. McIntyre CA, Winter JM. Diagnostic Evaluation and Staging of Pancreatic Ductal Adenocarcinoma. *Seminars in Oncology*. 2015;42(1):19-27.
12. Owyang C, Williams JA. Pancreatic secretion. *Yamada's Textbook of Gastroenterology*. 2015:450-73.
13. Jafari SH, Lajevardi ZS, Zamani Fard MM, Jafari A, Naghavi S, Ravaei F, et al. Imaging Techniques and Biochemical Biomarkers: New Insights into Diagnosis of Pancreatic Cancer. *Cell Biochemistry and Biophysics*. 2024:1-22.
14. Farr KP, Moses D, Haghighi KS, Phillips PA, Hillenbrand CM, Chua BH. Imaging modalities for early detection of pancreatic cancer: Current state and future research opportunities. *Cancers*. 2022;14(10):2539.
15. Krishnaraju VS, Kumar R, Mittal BR, Sharma V, Singh H, Nada R, et al. Differentiating benign and malignant pancreatic masses: Ga-68 PSMA PET/CT as a new diagnostic avenue. *European Radiology*. 2021; 31:2199-208.
16. Artinyan A, Soriano PA, Prendergast C, Low T, Ellenhorn JDI, Kim J. The anatomic location of pancreatic cancer is a prognostic factor for survival. *HPB*. 2008;10(5):371-6.
17. Storz P, Crawford HC. Carcinogenesis of Pancreatic Ductal Adenocarcinoma. *Gastroenterology*. 2020; 158(8):2072-81.
18. Muraki T, Reid MD, Pehlivanoglu B, Gonzalez RS, Sekhar A, Memis B, et al. Variant anatomy of the biliary system as a cause of pancreatic and peri-ampullary cancers. *HPB*. 2020; 22(12):1675-85.
19. Miura S, Kume K, Kikuta K, Hamada S, Takikawa T, Yoshida N, et al. Focal parenchymal atrophy and fat replacement are clues for early diagnosis of pancreatic cancer with abnormalities of the main pancreatic duct. *The Tohoku Journal of Experimental Medicine*. 2020;252(1):63-71.
20. Nakahodo J, Kikuyama M, Fukumura Y, Horiguchi S-i, Chiba K, Tabata H, et al. Focal pancreatic parenchyma atrophy is a harbinger of pancreatic cancer and a clue to the intraductal spreading subtype. *Pancreatology*. 2022; 22(8):1148-58.
21. Olesen SS, Phillips AE, Faghieh M, Kuhlmann L, Steinkohl E, Frøkjær JB, et al. Overlap and cumulative effects of pancreatic duct obstruction, abnormal pain processing, and psychological distress on patient-reported outcomes in chronic pancreatitis. *Gut*. 2022;71(12):2518-25.
22. Frøkjær JB, Olesen SS, Drewes AM. Fibrosis, atrophy, and ductal pathology in chronic pancreatitis are associated with pancreatic function but independent of symptoms. *Pancreas*. 2013;42(7):1182-7.
23. Fukui H, Onishi H, Nakamoto A, Tsuboyama T, Ota T, Yano K, et al. Pancreatic fibrosis by extracellular volume fraction using Contrast-enhanced computed tomography and relationship with pancreatic cancer. *Eur J Radiol*. 2022; 156:110522.
24. Rodallec M, Vilgrain V, Couvelard A, Rufat P, O'Toole D, Barrau V, et al. Endocrine Pancreatic Tumours and Helical CT: Contrast Enhancement Is Correlated with Microvascular Density, Histoprognostic Factors and Survival. *Pancreatology*. 2006;6(1):77-85. 25.
25. Elias J, Jr., Semelka RC, Altun E, Tsurusaki M, Pamuklar E, Zapparo M, et al. Pancreatic cancer: correlation of MR findings, clinical features, and tumor grade. *J Magn Reson Imaging*. 2007;26(6):1556-63.
26. Takeshima K, Kumada T, Toyoda H, Kiriya S, Tanikawa M, Ichikawa H, et al. Comparison of IV contrast-enhanced sonography and histopathology of pancreatic

- cancer. *American Journal of Roentgenology*. 2005;185(5):1193-200.
27. Thomas D, Radhakrishnan P. Tumor-stromal crosstalk in pancreatic cancer and tissue fibrosis. *Molecular cancer*. 2019;18(1):14.
 28. Li X, Zhou J, Wang X, Li C, Ma Z, Wan Q, et al. Pancreatic cancer and fibrosis: Targeting metabolic reprogramming and crosstalk of cancer-associated fibroblasts in the tumor microenvironment. *Frontiers in Immunology*. 2023; 14:1152312.
 29. Tempero MA, Malafa MP, Al-Hawary M, Behrman SW, Benson AB, Cardin DB, et al. Pancreatic adenocarcinoma, version 2.2021, NCCN clinical practice guidelines in oncology. *Journal of the National Comprehensive Cancer Network*. 2021;19(4):439-57.
 30. Reischl S, Ziegelmayer S, Graf M, Gawlitza J, Sauter AP, Steinhardt M, et al. CT Attenuation of Hepatic Pancreatic Cancer Metastases Correlates with Prognostically Detrimental Metastatic Necrosis. *J Clin Med*. 2023;12(23).